



Mammary duct ectasia with bloody nipple discharge in a 5-month-old infant: A case report

El Yamani Fouda^{a,*}, Al Shamrani Khaled^b, Ahmad Al Hamdi^b, Mohammed Al Jurebi^a, Hesham Dahlan^b, Saud Erwi^b, Firas Al Ahmari^b, Nauman Rana^a

^a General Surgery Department, Armed Forces Hospital Southern Region, Armed Forces Hospital Jizan, Jizan City, P.O Box101, Saudi Arabia¹

^b Family Medicine Department, Armed Forces Hospital Southern Region, Armed Forces Hospital Jizan, Jizan City, P.O Box101, Saudi Arabia¹

ARTICLE INFO

Article history:

Received 19 December 2016

Received in revised form 29 December 2016

Accepted 2 January 2017

Available online xxx

Keywords:

Mammary duct ectasia

Nipple discharge

Conservative management

ABSTRACT

Mammary ductal ectasia (MDE) with bloody nipple discharge (BND) appears to be exceptionally rare and presents a challenge for management to the consulting physician. We report A 5-month-old boy presented with a 3 weeks history of unilateral breast enlargement associated with intermittent spontaneous bloody nipple discharge. Ultrasound evaluation showed a 1.0 cm × 0.57 cm cystic mass in the right subareolar region with dilated ducts. Cytological evaluation of nipple discharge showed no malignant cells. The breast swelling and nipple discharge resolved spontaneously after 1 months without recurrence during the following 7 months. We conclude that mammary ductal ectasia is a benign and self-limited disorder in infancy and can be managed conservatively without any specific treatment to avoid unnecessary invasive surgical intervention.

© 2016 Published by Elsevier Ltd.

1. Introduction

Physiological Milky nipple discharge and breast enlargement occurs frequently in infants within the first few months of life. Such breast tissue hypertrophy is linked to placenta-transmitted maternal and fetal hormones [1]. Conversely, bloody nipple discharge (BND) appears to be extremely rare and presents a challenge for management to the consulting physician [2]. Myers and Kaplan first reported bloody nipple discharge in two neonates [3]. In adults BND can be associated with breast cancer, however all of the reported cases of BND involving infants, attribute cause to a benign pathology, primarily mammary ductal ectasia (MDE) [2]. Here, we report an otherwise healthy 5-month-old infant who exhibited bloody nipple discharge from his right nipple.

2. Presentation of case

A 5-month-old boy presented with a 3 weeks history of right-sided intermittent spontaneous blood stained nipple discharge. There was no history of trauma or bleeding diathesis in his family. There were no abnormalities in the patient's maternal medical history. The child was breastfed and the mother did not take any medications dur-

ing pregnancy or while breastfeeding. On physical examination, about 1-cm, non-tender, palpable mass was noted in the sub areolar region of the upper right breast without fever or signs of inflammation. When the mass was squeezed, dark brown nipple discharge appeared (Fig. 1a). The remainder of the physical examination was unremarkable, with normal male genitalia. A written informed consent was obtained from the patient's father for publication of this case report and accompanying images.

An sonomammogram revealed where a 1.0 cm × 0.57 cm cystic mass in the right sub areolar region with dilated ducts suggestive of duct ectasia (Fig. 1b). Culture of nipple discharge was negative. Cytological examination showed hemosiderin-laden macrophages, neutrophils, lymphocytes and ductal epithelial cells with no malignant cell. The laboratory investigations showed that total blood cell count, bleeding time and clotting time were normal. Hormonal serum levels, luteinizing hormone (LH: 2.34mIU/mL), follicle stimulating hormone (FSH: 0.532 mIU/mL), prolactin (Prolactin: 24.88 ng/mL), testosterone (testosterone: 01.025 ng/dL), thyroid stimulating hormone (TSH:1.29 mcU/mL), free triiodothyronine (FT3: 6.56 pmol/L) and free tetraiodothyronine (FT4: 16.56 pmol/L) were within the age-appropriate reference ranges.

Approximately after 3-weeks follow-up, the amount of bloody discharge was markedly diminished and became yellowish in color and resolved completely even with squeeze of breast tissue after one month (Fig. 2; a). Furthermore, his repeated sonomammography showed that the duct ectasia had improved (Fig. 2; b). The breast enlargement and the nipple discharge resolved without recurrence during the following 7 months follow up period.

* Corresponding author.

Email addresses: mani_fouda@yahoo.com (E.Y. Mohamed Fouda); khalidalshmrani@yahoo.com (A.S. Mohammad Khaled); ahmedelhamdi348@yahoo.com (A.H. Al Hamdi); maljuerbi@yahoo.com (M.H. Al Jurebi); heshamdahlan22@yahoo.com (H.M. Dahlan); sauderwi@yahoo.com (S.M. Erwi); firasalahmari@yahoo.com (F.S.A. Ahmari); numnanwer@yahoo.com (N.A. Rana)

¹ afhijzan@yahoo.com.

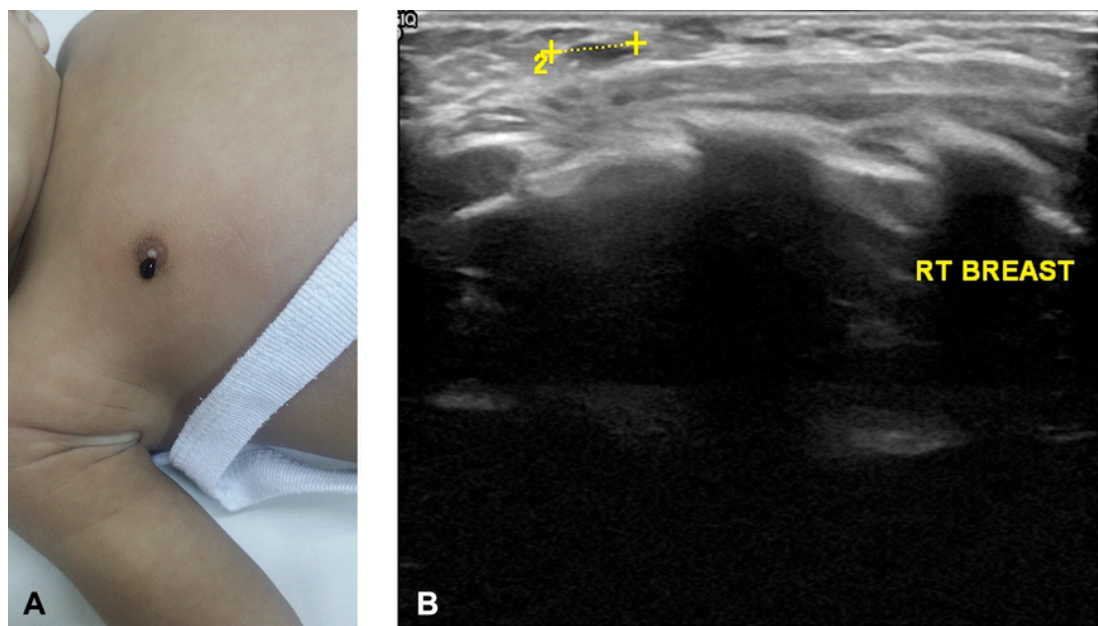


Fig. 1. a: Right breast enlargement with blood-stained nipple discharge. b: Right breast ultrasonography showing retareolar cystic lesion.

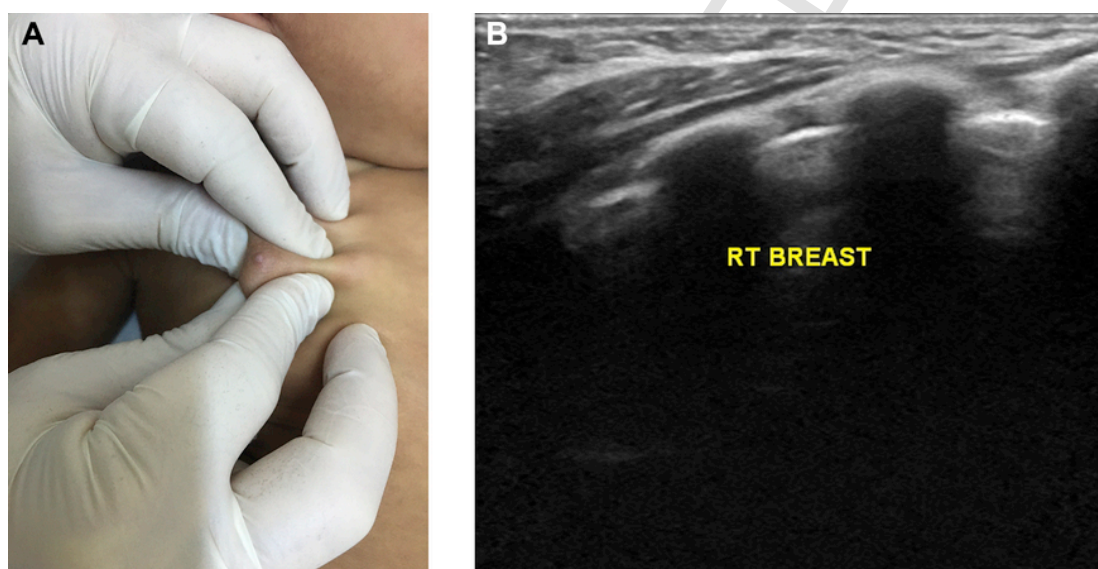


Fig. 2. a: Right breast enlargement and nipple discharge has been resolved. b: Right breast ultrasonography showing disappearance of the cystic lesion.

3. Discussion

Milky nipple discharge can be seen in the neonatal period. This benign condition is due to hormonal adaptation in the first months of life. However, bloody nipple discharge is rare in this period [2,4].

The underlying pathology of bloody nipple discharge differs by age group. In adulthood, BND is associated with benign pathology, such as intraductal papilloma, mammary ductal ectasia as well as malignant pathology [5]. In children, BND is almost always a benign condition, and is most often caused by mammary ductal ectasia [2,4,6,7].

Pervious series emphasized the importance of sonomammographic examination for bloody nipple discharges in infancy and

childhood. Review of 21 cases of bloody nipple discharges in children showed that 7 cases had sonomammographic examination and 6 of these 7 cases reported to have mammary ductal ectasia (MDE) [2]. Another study reported 46 cases of bloody nipple discharge (BND), in which 11 of 27 sonomammography results reported as MDE (nearly half of cases who had sonomammographic examination) [8].

Keeping in view the facts that sonomammogram of our child revealed benign looking sub areolar cystic dilated ducts and cytological examination revealed hemorrhagic, inflammatory and nonmalignant nature of discharge, diagnosis of mammary duct ectasia was made. Moreover there was no need excision of breast tissue excision, this is because the excised breast tissue specimens have consistently revealed benign duct ectasia and can cause psychological trauma as well as permanent breast damage [9]. Our diagnosis as benign mam-

mary duct ectasia was also supported by the fact that no case of primary breast malignancy in the first year of life has ever been reported.

The exact etiology of mammary duct ectasia in infants remains controversial. Although factors including congenital abnormalities of the breast development, maternal hormonal stimulation, trauma or autoimmune reaction have been implicated, neither was confirmed [2,6]. Some reports of bacterial infection from duct ectasia in children have been published, however this is inconsistent enough to be thought to be the etiological factor [10]. Hyperprolactinaemia is rarely cited as a cause of BND because hyperprolactinaemia usually presents with breast enlargement and a milky discharge, not with a bloody discharge [11].

In contrast to the female gender which predominate in the adult population, MDE is more prevalent in the males in infancy and childhood periods. In the previous reports the male to female ratio was 11:4 (2.75:1) [2,6,12,13], and in a recent wider review study, it is 28:18 (1.55:1) [8]. There is a wide range of the age at presentation of MDE, with infants as young as 20 days presenting with this disorder [14].

It is reasonable to assume that the extremely early onset of MDE with normal hormonal assay and there was no maternal history of abnormal hormones and lack of medications during pregnancy or while breastfeeding suggests the an association between the pathophysiology of mammary duct ectasia and developmental breast abnormalities. Moreover lack of clinical inflammatory evidence, negative culture for bacterial growth in our study disprove bacterial infection as a cause of the nipple discharge or breast enlargement.

The typical clinical presentation in children includes intermittent unilateral or bilateral BND, without any inflammatory signs and with or without associated breast hypertrophy or palpable mass [6]. Our child was presented by right sided blood stained nipple discharge and enlarged breasts with non-tender palpable mass. These latter findings do not affect the benign course of BND according to our study. Therefore, in the absence of other findings, we propose a similar investigation and follow-up pattern for unilateral BND in infants as our child improved without ipsilateral or contralateral recurrence.

Mammary duct ectasia accompanied by BND occurring in the neonatal and childhood periods is a self-limiting condition [4] and resolution may take 2 weeks to 9 months [15]. There is no clear benefit from any invasive diagnostic or surgical intervention, and the procedure may cause permanent deformity or dysfunction of the breast tissue [9]. However criteria for surgery include suspicious cytological results [15], lesions that continue to bleed [15–17], ultrasonographic findings of a mass or abnormality other than MDE [13,15], lesions that expand in size, presence of pain or tenderness [17] and BND that does not resolve within 9 months [14]. Our result of radiological evaluation, physical examination, investigation and follow up did not meet the criteria for surgical intervention. Also some authors recommended surgical intervention for a palpable mass or MDE with unilateral BND [2,16]. However, the unilateral breast enlargement resolved and the bloody nipple discharge disappeared spontaneously after 1 months follow-up period without Synchronous or Metachronous recurrence during the following 7 months as our study proved.

4. Conclusion

Our findings allow us to propose that ultrasound evaluation, and cytological examination of BND are sufficient in establishing the di-

agnosis of mammary duct ectasia as a cause of BND in childhood. Moreover, considering our patient and previous reports, unilateral MDE with blood stained nipple discharge can be management conservatively by careful clinical follow up without the need for biopsy or surgical intervention even if it is associated with breast enlargement.

Acknowledgment

I take this opportunity to express my deep sense of gratitude to doctor Hossam Taha Al Dorgham and doctor Hani Ahmed Abdelwahab, Hospital medical directors, Armed Forces Hospital Jizan, for their constant encouragement, cordial support throughout the course of my work, valuable information and guidance, which helped me in completing this task through its various stages.

References

- [1] S.S. Joseph, Breast disorders, in: R.M. Kliegman, R.E. Behrman, H.B. Jenson, B.F. Stanton (Eds.), *Nelson textbook of pediatrics*, eighteenth ed. Saunders Co, Philadelphia, 2007, pp. 2279–2282.
- [2] J.Y. Seo, S.J. Kim, S.J. Lee, et al., Bloody nipple discharge in an infant, *Korean J Pediatr* 53 (2010) 917–920.
- [3] M.B. Myers, I.W. Kaplan, Bleeding from the nipple in infancy due to cystic ductal hyperplasia of the breast, *Ann Surg* 143 (4) (1956) 557–560.
- [4] I.K. Bayrak, T. Yalin, M.S. Nural, M. Ceyhan, Mammary duct ectasia in infant breast with bloody nipple discharge: sonographic findings, *J Clin Ultrasound* 36 (2008) 229–230.
- [5] R. Kaplan, S.A. Hoda, R.S. Hoda, Cytological evaluation of bloody nipple discharge fluid, *Diagn Cytopathol* 41 (2013) 183–185.
- [6] M. McHoney, F. Munro, G. Mackinlay, Mammary duct ectasia in children: report of a short series and review of the literature, *Early Hum Dev* 87 (2011) 527–530.
- [7] P. Triantafyllou, G. Zardava, H. Maratou, et al., Recurrent bloody nipple discharge in a 3-year-old boy, *Acta Paediatr* 98 (2009) 1864.
- [8] T. Acer, M. Derbent, A. Hiçsönmez, Bloody nipple discharge as a benign, self-limiting disorder in young children: a systematic review including two related case reports, *J Pediatr Surg* 50 (11) (2015 Nov) 1975–1982.
- [9] C.D. Berkowitz, S.H. Inkelis, Bloody nipple discharge in infancy, *J Pediatr* 103 (1983) 755–756.
- [10] S. Kitahara, M. Wakabayashi, T. Shiba, K. Nonaka, H. Nonaka, I. Kobayashi, Mammary duct ectasia in children presenting bloody nipple discharge: a case in a pubertal girl, *J Pediatr Surg* 36 (2001) E2.
- [11] V.M. Kelly, K. Arif, S. Ralston, N. Greger, S. Scott, Bloody nipple discharge in an infant and a proposed diagnostic approach, *Pediatrics* 117 (2006) e814–e816.
- [12] A. Pampal, A. Gokoz, S. Tansu, et al., Bloody nipple discharge in 2 infants with interesting cytologic findings of extramedullary hematopoiesis and hemophagocytosis, *J Pediatr Hematol Oncol* 34 (2012) 229–231.
- [13] R. Tan, B.V. Bosstraeten, K. Casteels, Does bloody nipple discharge occur during normal breast development in infancy?, *Pediatr Int* 52 (2010) 825–843.
- [14] R. Aydın, S.B. Gul, A.V. Polat, Detection of duct ectasia of mammary gland by ultrasonography in a neonate with bloody nipple discharge, *Pediatr Neonatol* 55 (2014) 228–230.
- [15] E. Weimann, Clinical management of nipple discharge in neonates and children, *J Paediatr Child Health* 39 (2003) 155–156.
- [16] F. Corapçioğlu, G. Akanse, N. Sarper, et al., Mammary ductal ectasia as cause of bloody nipple discharge in a 28-month-old boy, *Turk J Pediatr* 47 (2005) 379–381.
- [17] J.D. Miller, M.D. Brownell, A. Shaw, Bilateral breast masses and bloody nipple discharge in a 4-year-old boy, *J Pediatr* 116 (1990) 744–747.